



# Morgellons disease: the mystery unfolds

Virginia R Savely and Raphael B Stricker<sup>†</sup>

**Morgellons disease is a mysterious skin disorder that was first described over 300 years ago. The disease is characterized by fiber-like strands extruding from the skin in association with dermatologic and neuropsychiatric signs and symptoms. Although Morgellons disease has been confused with delusional parasitosis, the occurrence of the disease in children, the lack of pre-existing psychopathology in most patients and the presence of subcutaneous fibers on skin biopsy indicate that the disease has a somatic origin. The association with Lyme disease and the apparent response to antibiotic therapy supports the concept that Morgellons disease may be triggered by an infectious process. Recent studies suggest that infection with *Agrobacterium* may play a role in the disease. Further clinical and molecular research is needed to unlock the mystery of Morgellons disease.**

*Expert Rev. Dermatol.* 2(5), 585–591 (2007)

Morgellons disease is a mysterious illness characterized by nonhealing skin lesions associated with crawling or stinging sensations under the skin and the presence of fiber-like strands and granule-like objects protruding from the lesions [1]. The disease was first described in French children in 1674 by a British physician, Sir Thomas Browne, as follows [2]:

*“Hairs which have most amused me have not been in the face or head, but on the back, and not in men but children, as I long ago observed in that endemic distemper of little children in Languedock, called the Morgellons, wherein they critically break out with harsh hairs on their backs, which takes off the unquiet symptoms of the disease, and delivers them from coughs and convulsion.”*

In 1682, Dr Michel Ettmuller's microscopic drawings of objects associated with what was then believed to be a worm infestation of children (FIGURE 1) appear similar to microscopic views of fibers from present-day sufferers of this disease [2].

Morgellons disease was rediscovered in 2001 by a Pennsylvania housewife, Mary Leitao, who noted skin lesions with protruding fibers in her 2-year-old son. Unable to find medical help for

his condition, she founded the Morgellons Research Foundation [101], which began accepting registrations from people with symptoms of this unrecognized disease in 2002. The original focus of the foundation was on skin symptoms, but it soon became evident that other symptoms within this patient group, such as disabling fatigue, life-altering cognitive decline, musculoskeletal pain and mood disorders were of much greater concern.

Morgellons disease was initially considered to be a form of delusional parasitosis (DP) by most dermatologists [3–11]. However, as the disease has become more widely recognized, significant clinical differences from DP have become apparent (as discussed later) [12,13,102]. The recent discovery of a putative infectious cause of the disease supports a somatic etiology of this bizarre skin condition.

## Case definition

The Morgellons Research Foundation lists seven primary signs and symptoms of the condition:

- Skin lesions accompanied by intense itching
- Crawling sensations on and under the skin, often compared to insects moving, stinging or biting (cutaneous dysesthesia)

## CONTENTS

- Case definition
- Epidemiology & transmission
- Pathophysiology
- Differential diagnosis & association with Lyme disease
- Treatment
- Discussion
- Conclusions
- Key issues
- Expert commentary
- Five-year view
- Financial & competing interests disclosure
- References
- Affiliations

<sup>†</sup>Author for correspondence  
International Lyme and Associated  
Diseases Society (ILADS),  
PO Box 341461, Bethesda,  
MD 20827-1461, USA  
Tel.: +1 415 399 1035  
Fax: +1 415 399 1057  
rstricker@usmamed.com  
www.ilads.org

**KEYWORDS:**  
*Agrobacterium*, *Borrelia burgdorferi*, delusional parasitosis, Lyme disease, Morgellons

- Fibers, which can be white, blue, red or black, in and on the lesions
- Fatigue significant enough to interfere with daily activity
- Musculoskeletal pain
- Inability to concentrate and difficulty with short-term memory
- Behavioral changes

Patients with Morgellons disease typically have skin lesions that can range from minor to disfiguring in appearance (FIGURES 2 & 3). A network of blue, red, white and black fibers under the skin of these patients as well as blue, black and white fibers protruding from the lesions can be visualized using a 30× hand-held digital microscope (FIGURE 3). Attempts to remove the tough filaments protruding from skin lesions induces shooting pains radiating from the site, indicating that the filaments are not simply adsorbed to the skin and may be quite resistant to extraction.

The fiber-like material can be observed in skin lesions as either single strands or what appear to be balls of fibrous material that may demonstrate autofluorescence (FIGURE 4) [1]. Patients frequently describe this material as ‘fibers’, ‘fiber balls’ or ‘fuzz balls’. Granules protruding from the skin of patients can often be seen microscopically to have one or more fibers attached at the ends. Patients often describe these granules as ‘seeds’, ‘eggs’ or ‘sand’ [1]. Many individuals report material described as ‘black specks’ or ‘black oil’. Some patients have no observable skin lesions, with the skin sensations and fibrous, granular or black material being the only visible indicator of the disease [1].

According to statistics from the Morgellons Research Foundation, 95% of patients report symptoms of disabling fatigue, self-described ‘brain fog’ or attention deficit, while 50% of patients report problems with fibromyalgia, joint pain and sleep disorders. Other symptoms include hair loss, decline in vision, neurological disorders and occasionally tooth decay despite the lack of caries or gingivitis. Most patients are unable to continue working, and those who do work report that they do not function optimally [1].

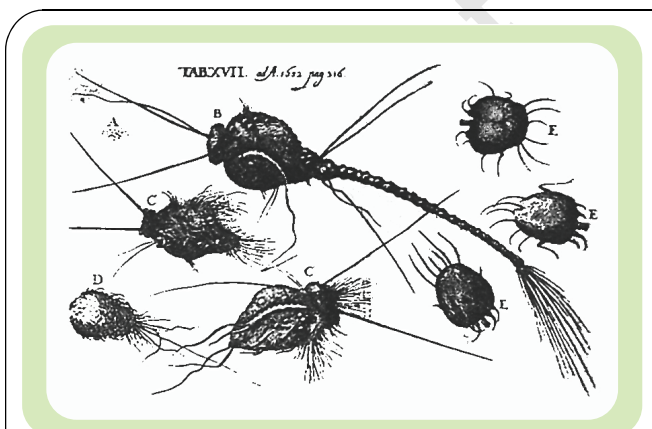


Figure 1. Etmuller's drawings of Morgellons fibers, 1682. Reproduced with permission of the Morgellons Research Foundation. For a historical perspective see [2].

Patients with this disease are often diagnosed with a psychosomatic illness by the dermatologists whom they consult for care [3–11]. Typically, patients have sought help from 10–40 physicians who often make a diagnosis of DP without a thorough examination and interpret the obvious open sores on the patient's skin as attempts at self-mutilation [12]. One patient described his experience with Morgellons disease in this way [1]:

*“I have had this disease for 20 years. I spent the first 10 years going from doctor to doctor for help. I spent the last 10 years just living with it, knowing that no one would ever help me.”*

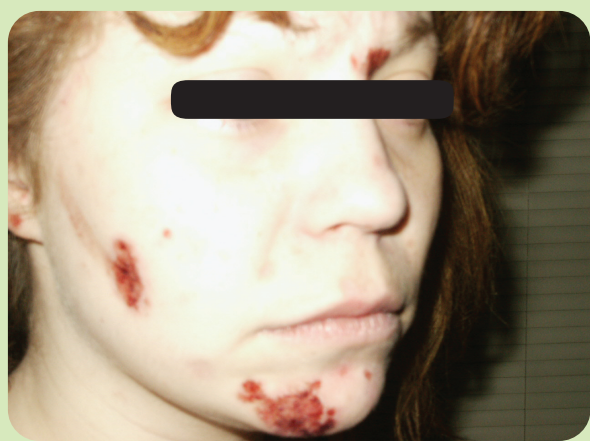Patients often exhibit psychopathology that appears to be directly attributable to the disease. This fact confounds the clinical picture for patients as they seek validation for an insidious dermatologic condition while exhibiting obvious symptoms of mental illness [1]. It appears that the putative underlying infectious disease, left unrecognized and untreated, can cause psychopathology in many patients. This aspect of Morgellons disease appears to be analogous to the clinical course of infection with *Treponema pallidum*, the spirochetal agent of syphilis that can cause dermatologic and neuropsychiatric pathology at different stages of infection. The syphilis model underscores a basic premise of psychosomatic dermatology: the diagnosis of a delusional disorder must be based on the presence of a primary psychiatric disorder rather than the absence of known dermatopathology [1]. In the case of Morgellons disease, a poorly characterized dermatologic condition appears to trigger secondary psychopathology that may be wrongly confused with a primary delusional disorder [1].

#### Epidemiology & transmission

The states of California, Texas and Florida in the USA appear to have the highest number of reports of this disease, with primary clusters noted in Los Angeles and San Francisco (CA) and Houston, Dallas and Austin (TX). California accounts for 26% of cases in the USA. All 50 states and 15 nations, including Canada, England, Australia and The Netherlands have reported cases of Morgellons disease. The total number of registrations on the Morgellons Research Foundation website is presently over 10,000, which is believed to be a fraction of the actual number of cases. We currently follow more than 200 Morgellons patients in our practice in San Francisco.

Initially, Morgellons disease was thought to be more prevalent in nurses and teachers, but that finding has not been substantiated. The male to female ratio is approximately 1:1 according to the Morgellons Research Foundation. The disease affects all age groups including children, but the prevalence in children is unknown at present. There is often a history of traumatic exposure to plants, dirt or soil, such as gardening, landscaping, farming, camping or other outdoor activities. The association with plant exposure has implications for the etiology of the disease (as discussed later).

It appears that skin lesions and fibers may not be present in all individuals with this disease, since family members of patients often report similar systemic symptoms without skin lesions [1].



**Figure 2. Clinical appearance of Morgellons skin lesions on the face.**  
Used with permission of the patient.

Whether the disease is transmissible by human contact remains unclear, but preliminary evidence suggests that it is not. Although most sufferers are fearful of infecting family members, the rare instances where all family members are affected appear to have a common exposure to an inciting agent [1].

Patients have reported symptoms of this disease in their pets [1]. The majority of reports involve dogs, but cats appear to be increasingly affected. Skin lesions fitting the description of Morgellons disease have also been reported in horses, and horse owners have observed fibers associated with skin lesions on their animals by using a lighted 30× hand-held microscope [1].

### Pathophysiology

Skin biopsies of patients typically reveal nonspecific pathology, or an inflammatory process with no observable pathogens [1]. Several biopsies have shown fibrous material projecting from inflamed epidermal tissue. Often the biopsies are reported to contain 'textile fibers' located in the dermal region rather than being adherent to the skin. How these fibers arrive at a subcutaneous location remains unexplained. It has been postulated that the fibrous (and other) material associated with skin lesions may be linked to the biofilm of a bacteria, *Stenotrophomonas maltophilia* [SCHWARTZ G, PERS. COMM. 2005], but this hypothesis has not been confirmed [13]. Recent studies indicate that Morgellons fibers are resistant to chemical solubilization and heating, making analysis difficult by conventional means [13].

There is preliminary information that some Morgellons fibers are made of cellulose, but this information has neither been formally evaluated nor confirmed [1]. In a classic study, Hall *et al.* identified fibers composed of a cellulose–protein complex as a minor constituent of mammalian connective tissue, and increased amounts of these fibers were noted in tissue from patients with scleroderma and other pathological skin conditions [14]. More recent research has demonstrated synthesis of cellulose fibers by certain Gram-negative bacteria and fungi [15–18]. Studies using newer carbohydrate microarray technologies may unlock the mystery of these fibers [19].

By contrast to mammalian studies, cellulose is known to be produced in copious quantities by plant bacteria [15]. This observation led to investigation of plant pathogens in Morgellons disease. In a preliminary study, skin biopsies from Morgellons patients revealed evidence of infection with *Agrobacterium*, which causes crown gall disease in plants [20]. *Agrobacterium* is unique among plant pathogens because it can infect human cells *in vitro*, and sporadic cases of catheter sepsis due to *Agrobacterium* have been reported in immunocompromised patients [21,22]. The presence of *Agrobacterium* in Morgellons skin lesions suggests that this plant bacterium may be involved in the pathogenesis of the disease. Further investigation is required to confirm this novel hypothesis.

### Differential diagnosis & association with Lyme disease

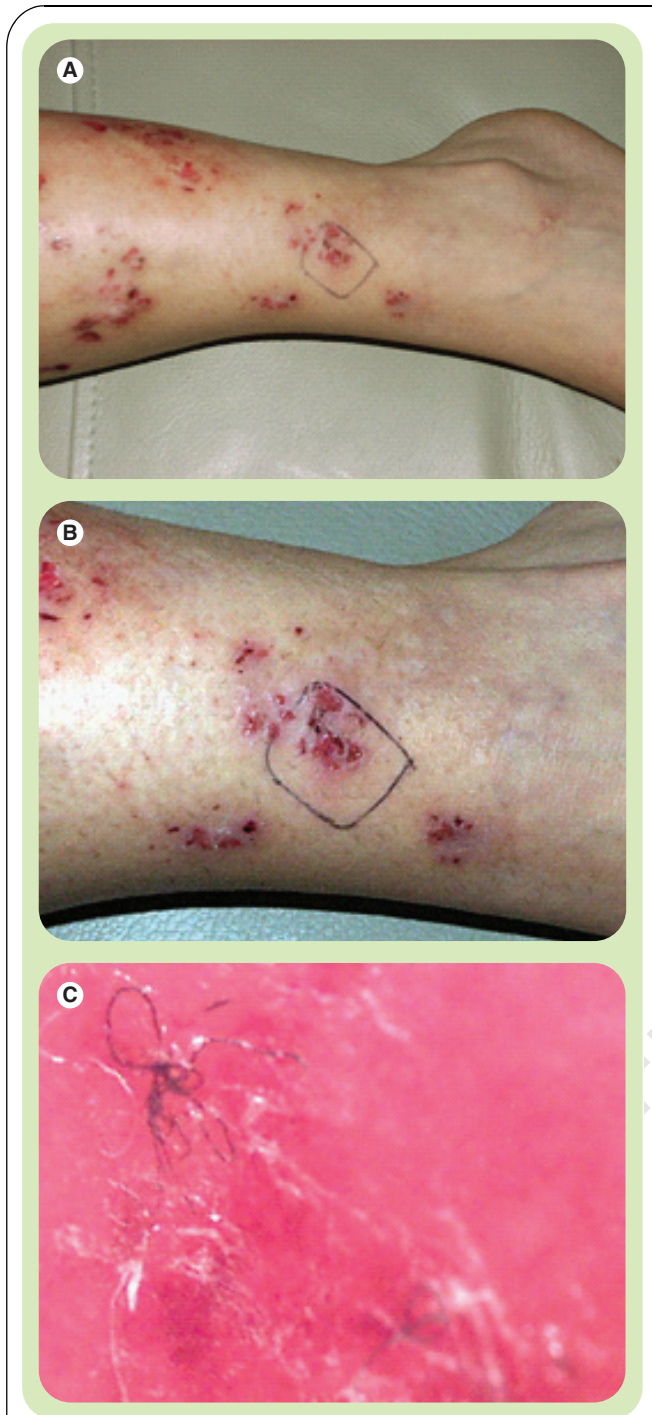The differential diagnosis of Morgellons disease includes DP, drug-induced formication, scabies, the tropical dermatoses and the perforating dermatoses.

DP, or Eckbom's syndrome, is a psychiatric disorder in which patients mistakenly believe that they are infested with a skin parasite [3–11]. Patients often refuse to accept a psychiatric diagnosis for their skin symptoms and continue to insist that they have a parasitic infestation. Physicians are taught about the 'matchbox sign' of DP, so-called because patients use a matchbox to carry samples of hair, lint or fuzz to the physician in an attempt to provide evidence of the agent responsible for their torment. When two people describe symptoms of DP, the condition is termed *folie à deux* (madness of two) [7]. There is also *folie à trois* (madness of three) and *folie à quatre* (madness of four). DP affecting all members of a family is considered *folie à famille* (madness of family) [8]. Antipsychotic medications such as pimozide or risperidone are often prescribed for these patients [3,8]. A recent study from India found that DP occurred in only 2% of patients with primary psychiatric conditions (bipolar disorder, depression, schizophrenia or anxiety disorder). Conversely, 100% of patients diagnosed with DP had an underlying primary psychiatric diagnosis [23].

Morgellons disease is distinct from DP in a number of ways. First, the disease may be diagnosed in children who generally do not develop delusional disorders. Second, while DP almost always occurs in patients with underlying psychopathology who otherwise can function fairly normally [24], most Morgellons patients have no signs of pre-existing psychiatric illness and have significant impairment in functioning. Third, the epidemiology of Morgellons disease (outlined previously) differs from delusional disease: the latter is extremely rare in the USA with a prevalence estimated at 0.03%, and usually occurs in middle-aged or older women. Finally, the association with a putative bacterial agent suggests that Morgellons disease has a somatic rather than a psychiatric etiology [24–27].

Drug-induced formication (a false sensation of bugs crawling on the skin) is a sensory hallucination induced by psychostimulant drugs such as cocaine or amphetamines [28]. The hallucination has been referred to as 'coke mites', 'meth mites' or 'amphetamines' depending on the offending agent.





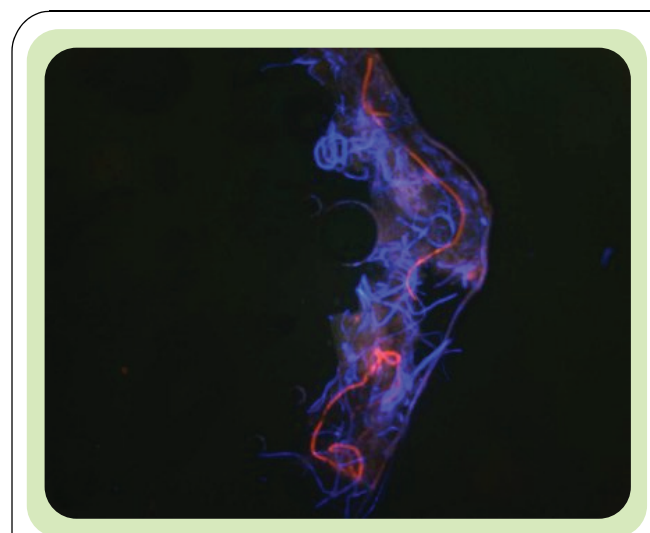
**Figure 3. Clinical appearance of Morgellons skin lesions. (A & B)** Gross appearance of leg lesions. **(C)** Appearance of subcutaneous fibers under x60 digital microscope. Used with permission from Charles Holman.

Patients with this drug-induced disorder often develop skin lesions due to picking and scratching of accessible skin areas. By contrast, patients with Morgellons disease usually have no history of psychostimulant drug use, and their skin lesions feature perforating fibers that occur at inaccessible locations on the body.

Scabies is a pruritic skin disease caused by infestation with the microscopic mite *Sarcoptes scabiei* [29]. The infestation is found primarily in the webbing between the fingers and in the skin folds on the wrist, elbow or knee. Intense itching may occur especially at night and over most of the body. Lack of the typical scabies skin distribution and the absence of mite infestation distinguishes scabies from Morgellons disease.

The tropical dermatoses are pruritic skin disorders caused by parasitic infections, including filariasis, onchocerciasis and cutaneous larva migrans [30–32]. These dermatoses are prevalent in the tropics, and the skin lesions are associated with eosinophilia, lymphatic obstruction (filariasis), subcutaneous nodules (onchocerciasis) or serpiginous skin lesions (larva migrans). The causative nematode is detected in skin biopsy samples. By contrast, tropical travel and eosinophilia are not commonly reported in Morgellons patients and nematodes have not been identified in skin biopsy samples from these individuals. However, the tropical dermatoses may respond to treatment with antiparasitic medications such as ivermectin and thiabendazole [30–32] and antiparasitic therapy may be useful in treating Morgellons disease.

The perforating dermatoses are a group of skin diseases characterized by elimination of elastic or collagen fibers from the upper dermis through the skin [33–36]. There are five members of this group: Kyrle's disease, perforating folliculitis, reactive perforating collagenosis, elastosis perforans serpiginosa and acquired perforating dermatosis [33]. The perforating dermatoses are associated with hereditary diseases including Ehlers–Danlos syndrome, osteogenesis imperfecta, Down syndrome and Wilson's disease. They may also be seen in patients with brittle diabetes mellitus or dialysis-dependent renal failure [33–36]. These dermatoses are distinct from Morgellons disease because the protruding fibers are made up of elastic or collagenous tissue that is easily identified by histopathology [34]. In addition, Morgellons patients generally do



**Figure 4. Autofluorescence of fibers from Morgellons skin lesion.**

Courtesy of the Morgellons Research Foundation, all rights reserved, used with permission. For more details see [1].

not have the rare hereditary conditions or severe metabolic abnormalities associated with the perforating dermatoses. Conversely, systemic infection and neuropsychiatric symptoms have not been associated with these dermatoses, and they do not respond to antibiotic therapy [33–36].

Many patients with Morgellons disease have positive testing for tick-borne pathogens including *Borrelia burgdorferi* – the spirochetal agent of Lyme disease [1]. It appears that there may be a connection between the two diseases, with one infection possibly predisposing the individual to a second infectious agent. Whether all patients with Morgellons disease also have Lyme borreliosis remains to be determined. An intriguing possibility is that the agent of Morgellons disease is transmitted by a tick bite. Since ticks are known to harbor plant bacteria [37], transmission of these pathogens via tick bite may allow the otherwise nonpathogenic plant bacteria to induce disease in the human host. Support for this hypothesis is lacking at present.

### Treatment

Treatment of Morgellons disease is problematic. Since the etiologic agent of the disease is unknown at present, the optimal treatment approach remains undefined [1]. Antipsychotic medications used to treat DP have not been effective for Morgellons patients, although compliance with these medications has been questionable in many cases. Treatment with antibiotics appears to be the most effective therapy for the disease [1,12]. Although standard antibiotic therapy for Lyme disease may be helpful in some cases, the response rate appears to be variable. Treatment with antiparasitic medications may be effective in other cases, and combinations of antibacterial, antiparasitic and antifungal medications may be useful.

It is noteworthy that *Agrobacterium* is extremely resistant to antibiotics in immunocompromised patients, even though the microbe appears to be sensitive to these antimicrobials *in vitro* [21]. A similar situation may exist in Morgellons patients who harbor an adapted strain of the bacteria. This possibility and its ramifications for the treatment of Morgellons disease require further study.

### Discussion

Morgellons disease remains controversial, and many physicians are convinced that the disease is simply a manifestation of DP [9–11]. In this regard, it is noteworthy that the medical world has always been reluctant to adopt new paradigms or concepts of disease [38]. As examples, the Hungarian physician Ignaz Semmelweis was ridiculed in the 1850s for suggesting that childbed fever was caused by an infectious agent, and the term ‘Semmelweis reflex’ was coined to describe automatic dismissal or rejection of scientific information “without thought, inspection, or experiment” [39]. In the early 1900s, syphilitic patients were confined to mental institutions before it was realized that they were suffering from an infectious disease, while more recently, the medical community took years to accept the fact that peptic ulcer

disease is caused by the infectious agent *Helicobacter pylori*, or that spongiform encephalopathy is caused by a novel prion agent.

In the case of Morgellons disease, the medical community may be ignoring an unusual and previously unrecognized infection, consigning patients to frustration and suffering by not validating or attempting to treat this infection [1]. The growing number of patients with symptoms of Morgellons disease who lack the typical features of DP supports the idea that these patients are suffering from a puzzling infectious disease that may cause horrific symptoms and psychiatric sequelae.

Until a formal study of Morgellons disease is accomplished, the cause, transmission and treatment of the disease will remain uncertain [12,13,102]. Following the death of a young Morgellons patient in 2006 and the widespread publicity generated by that incident, the CDC initiated an investigation in an attempt to validate the existence of the disease [40]. The formal report of the CDC investigation is eagerly awaited.

### Conclusions

More than 300 years after its initial description, Morgellons disease remains a medical mystery. In view of the uncertainty surrounding the disease, medical practitioners must look beyond what they have been taught when confronted with new and puzzling symptoms in patients. Rather than being quick to pigeonhole Morgellons patients into a psychiatric diagnosis such as DP, practitioners should take patient complaints seriously and keep an open mind about this potentially novel infectious disease. Recognition of Morgellons disease serves as a reminder to medical practitioners that we have much to learn from listening to the patient. At the same time, newer molecular techniques will hopefully unlock the secrets of this devastating illness.

### Key issues

- Morgellons disease is a mysterious illness whose cause remains undefined.
- Patients develop skin lesions with multicolored fluorescent fibers visible under the skin in association with musculoskeletal and neuropsychiatric symptoms.
- Morgellons disease is often confused with delusional parasitosis, but its occurrence in children and in adults without pre-existing or concurrent psychiatric illness suggests that the disease has a somatic origin.
- Morgellons disease is often found in patients with Lyme disease and related tick-borne coinfections.
- Preliminary evidence suggests an association between Morgellons disease and infection with *Agrobacterium*, a plant bacterium that may be harbored by ticks.
- Treatment of Morgellons disease is empirical and involves the use of antibacterial, antiparasitic and antifungal medications.

### Expert commentary

Owing to uncertainty about the cause of Morgellons disease, the optimal treatment for this dermatologic syndrome remains unclear. At this time, empirical therapy with combinations of antibacterial, antiparasitic and antifungal medication is indicated to control the disease. Treatment of associated Lyme disease and related tick-borne coinfections is also essential in these patients. Once the causative agent of Morgellons disease is defined, more effective treatment strategies can be developed.

### Five-year view

As more patients are diagnosed with Morgellons disease, the syndrome will be officially recognized by government agencies as an emerging infectious disease. Molecular research will confirm that the disease is caused by infection with a plant bacterium that is transmitted by a tick bite. Further work with this bacterial agent will define the optimal antibiotic therapy for patients with the disease. Development of more potent disease-specific antibiotics

will allow more effective therapy of Morgellons patients. The novel concept of a plant bacterium infecting humans will open a new field of microbiology – xenobacteriology.

### Acknowledgments

The authors thank Vitaly Citovsky, Kerry Clark, Keith Clay, William Harvey, Alan MacDonald, James Schaller, Randy Wymore and Adi Zaltsman for helpful discussion. We also thank Mary Leitao, Pat Smith and Cindy Casey for their invaluable contributions, and Mr and Mrs Robert Weinke for their generous support. This article is dedicated to the memory of Charles Holman.

### Financial & competing interests disclosure

*RB Stricker serves on the advisory panel for QMedRx Inc. The authors have no other relevant affiliations or financial involvement with any organization or entity with a financial interest in or financial conflict with the subject matter or materials discussed in the manuscript apart from those disclosed.*

*No writing assistance was utilized in the production of this manuscript.*

### References

Papers of special note have been highlighted as:

• of interest

•• of considerable interest

- Savely VR, Leitao MM, Stricker RB. The mystery of Morgellons disease: infection or delusion? *Am. J. Clin. Dermatol.* 7, 1–5 (2006).
- **First description of Morgellons disease in peer-reviewed medical literature.**
- Kellett CE. Sir Thomas Browne and the disease called the Morgellons. *Ann. Medical History* 7, 467–469 (1935).
- **Historical view of Morgellons disease.**
- Koo J, Gambla C. Delusions of parasitosis and other forms of monosymptomatic hypochondriacal psychosis. General discussion and case illustrations. *Dermatol. Clin.* 14, 429–438 (1996).
- Koo J, Lee CS. Delusions of parasitosis. A dermatologist's guide to diagnosis and treatment. *Am. J. Clin. Dermatol.* 2, 285–290 (2001).
- **Review of delusional parasitosis.**
- Wilson FC, Uslan DZ. Delusional parasitosis. *Mayo Clin. Proc.* 79, 1470 (2004).
- Bourgeois ML, Duhamel P, Verdoux H. Delusional parasitosis: folie a deux and attempted murder of a family doctor. *Br. J. Psychiatry* 161, 709–711 (1992).
- Daniel E, Srinivasan TN. Folie a famille: delusional parasitosis affecting all the members of a family. *Indian J. Dermatol. Venereol. Leprol.* 70, 296–297 (2004).
- Lorenzo CR, Koo J. Pimozide in dermatologic practice: a comprehensive review. *Am. J. Clin. Dermatol.* 5, 339–349 (2004).
- Murase JE, Wu JJ, Koo J. Morgellons disease: a rapport-enhancing term for delusions of parasitosis. *J. Am. Acad. Dermatol.* 55, 913–914 (2006).
- Waddell AG, Burke WA. Morgellons disease? *J. Am. Acad. Dermatol.* 55, 914–915 (2006).
- Koblentz CS. The challenge of Morgellons disease. *J. Am. Acad. Dermatol.* 55, 920–922 (2006).
- Harvey WT. Morgellons disease. *J. Am. Acad. Dermatol.* 56, 705–706 (2007).
- Wymore RS, Casey RL, Allen RW *et al.* Physical evidence in Morgellons disease. Presented at: *The 14th International Molecular Medicine Tri-Conference*. San Francisco, CA, USA, 27 February–2 March 2007.
- Hall DA, Happey F, Lloyd PF, Saxl H. Oriented cellulose as a component of mammalian tissue. *Proc. R. Soc. Lond. B Biol. Sci.* 151, 497–516 (1960).
- Matthysse AG, White S, Lightfoot R. Genes required for cellulose synthesis in *Agrobacterium tumefaciens*. *J. Bacteriol.* 177, 1069–1075 (1995).
- Bertocchi C, Delneri D, Signore S, Weng Z, Bruschi CV. Characterization of microbial cellulose from a high-producing mutagenized *Acetobacter pasteurianus* strain. *Biochim. Biophys. Acta* 1336, 211–217 (1997).
- Brown RM. Cellulose structure and biosynthesis. *Pure Appl. Chem.* 71, 204–212 (1999).
- Ude S, Arnold DL, Moon CD, Timms-Wilson T, Spiers AJ. Biofilm formation and cellulose expression among diverse environmental *Pseudomonas* isolates. *Environ. Microbiol.* 8, 1997–2011 (2006).
- Wang D. Carbohydrate microarrays. *Proteomics* 3, 2167–2175 (2003).
- Stricker RB, Savely VR, Zaltsman A, Citovsky V. Contribution of *Agrobacterium* to Morgellons disease. *J. Invest. Med.* 55, S123 (2007).
- **First description of *Agrobacterium* in Morgellons patients.**
- Giammanco GM, Pignato S, Santangelo C, Grimont PA, Grimont F, Giammanco G. Molecular typing of *Agrobacterium* species isolates from catheter-related bloodstream infections. *Infect. Control Hosp. Epidemiol.* 25, 885–887 (2004).
- **Overview of opportunistic *Agrobacterium* bacteremia in humans.**
- Kunik T, Tzfira T, Kapulnik Y, Gafni Y, Dingwall C, Citovsky V. Genetic transformation of HeLa cells by *Agrobacterium*. *Proc. Natl Acad. Sci. USA* 98, 1871–1876 (2001).
- **Seminal article showing transformation of human cells by *Agrobacterium*.**
- Kuruvila M, Gahalaut P, Zacharia A. A study of skin disorders in patients with primary psychiatric conditions. *Indian J. Dermatol. Venereol. Leprol.* 70, 292–295 (2004).
- American Psychiatric Association. *Diagnostic and Statistical Manual of Mental Disorders, Fourth Edition. Text Revision (DSM-IV-TR)*. APA, Washington, DC, USA (2000).
- Manschreck TC. Delusional disorder: the recognition and management of paranoia. *J. Clin. Psychiatry* 57(Suppl. 3), 32–38 (1996).

- **Overview of epidemiology of delusional disorders.**
- 26 Koo J, Gambla C, Fried R. Pseudopsychodermatologic disease. *Dermatol. Clin.* 14, 525–530 (1996).
- **Reminder that somatic diseases may be misdiagnosed as psychosomatic disorders.**
- 27 Ford EB, Calfee DP, Pearson RD. Delusions of intestinal parasitosis. *South. Med. J.* 94, 545–547 (2001).
- 28 Clark T. Photoessay: formication. *Consultant* 46, 1512–1513 (2006).
- 29 Wendel K, Rompalo A. Scabies and pediculosis pubis: an update of treatment regimens and general review. *Clin. Infect. Dis.* 35(Suppl. 2), S146–S151 (2002).
- 30 Melrose WD. Chemotherapy for lymphatic filariasis: progress but not perfection. *Expert Rev. Anti Infect. Ther.* 1, 571–577 (2003).
- 31 Brieger WR, Awedoba AK, Eneanya CI *et al.* The effects of ivermectin on onchocercal skin disease and severe itching: results of a multicentre trial. *Trop. Med. Int. Health* 3, 951–961 (1998).
- 32 Shinkar RM, Stocks R, Thomas E. Cutaneous larva migrans, creeping eruption, sand worm. *Arch. Dis. Child.* 90, 998 (2005).
- 33 Sehgal VN, Jain S, Thappa DM, Bhattacharya SN, Logani K. Perforating dermatoses: a review and report of four cases. *J. Dermatol.* 20, 329–340 (1993).
- 34 Rapini RP, Herbert AA, Drucker CR. Acquired perforating dermatosis. Evidence for combined transepidermal elimination of both collagen and elastic fibers. *Arch. Dermatol.* 125, 1074–1078 (1989).
- 35 Mehta RK, Burrows NP, Payne CM, Mendelsohn SS, Pope FM, Rytina E. Elastosis perforans serpiginosa and associated disorders. *Clin. Exp. Dermatol.* 26, 521–524 (2001).
- 36 Becuwe C, Dalle S, Ronger-Savle S *et al.* Elastosis perforans serpiginosa associated with pseudo-pseudoxanthoma elasticum during treatment of Wilson's disease with penicillamine. *Dermatology* 210, 60–63 (2005).
- 37 Benson MJ, Gawronski JD, Eveleigh DE, Benson DR. Intracellular symbionts and other bacteria associated with deer ticks (*Ixodes scapularis*) from Nantucket and Wellfleet, Cape Cod, Massachusetts. *Appl. Environ. Microbiol.* 70(1), 616–620 (2004).
- **Demonstration of plant bacteria in ticks.**
- 38 Kuhn TS. *The Structure of Scientific Revolutions (2nd Edition)*. University of Chicago Press, IL, USA (1970).
- 39 Grant GJ, Grant AH, Lockwood CJ. Simpson, Semmelweis, and transformational change. *Obstet. Gynecol.* 106, 384–387 (2005).
- 40 Morris E. Mysterious 'Morgellons disease' prompts US investigation. *Nature Med.* 12, 982 (2006).

#### Websites

- 101 Morgellons Research Foundation [www.morgellons.org/](http://www.morgellons.org/)
- 102 Morgellons disease: managing a mysterious skin condition. [www.mayoclinic.com/health/morgellons-disease/SN00043](http://www.mayoclinic.com/health/morgellons-disease/SN00043)

#### Affiliations

- Virginia R Savely, RN, FNP-C  
International Lyme and Associated Diseases Society (ILADS), PO Box 341461, Bethesda, MD 20827-1461, USA  
Tel.: +1 415 399 1035  
Fax: +1 415 399 1057  
[lymesf@gmail.com](mailto:lymesf@gmail.com)  
[www.ilads.org](http://www.ilads.org)
- Raphael B Stricker, MD  
International Lyme and Associated Diseases Society (ILADS), PO Box 341461, Bethesda, MD 20827-1461, USA  
Tel.: +1 415 399 1035  
Fax: +1 415 399 1057  
[rstricker@usmamed.com](mailto:rstricker@usmamed.com)  
[www.ilads.org](http://www.ilads.org)